

Focal Therapy – Brief Overview and Focal Cryo Experience at P10A

Duke K. Bahn, MD • Prostate Institute of America (www.P10A.ORG) • Ventura, California (805) 585-3082 or (888) 234-0004

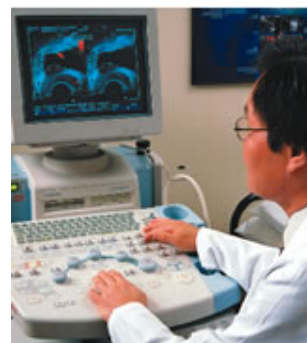


INTRODUCTION: The progression of clinically localized prostate cancer is usually slower than other cancers, and has confounded the development of a national consensus regarding the optimal treatment for the disease. In addition, most of the observers believe that screening with PSA can result in the over-treatment of prostate cancer. However, the justification for PSA screening and treatment is still accepted by most experts due to the estimated 27,540 death from this disease last year in the United States. Although some prostate cancers are aggressive, the relatively slow growing nature of clinically localized prostate cancer has refuted the current established treatment options for the disease. This argument is supported by the fact that about one third men over 50 years of age will display incidental prostate cancer at autopsy, but only 10 – 16% will develop invasive prostate cancer during their life time, and only 2.5%

will die from it.

Current treatment options for prostate cancer (PC) are either active surveillance or radical intervention treating the entire prostate (surgery, radiation, and others). Radical therapy may maximize the cancer control, but with a certain degree of sexual and urinary complications which may seriously affect quality of life. Active surveillance will not impact a patient's sexual and urinary function, but it can carry the psychological burden of missing the window of opportunity for cure for some men.

This article reviews many forms of novel approaches that are called "focal therapy" or "subtotal therapy". The goal of this approach is not only to achieve the same level of cancer control as seen in radical therapy, but also to maintain few or no complications in a selected group of men who have early stage organ- confined disease.



Dr Bahn has been targeting prostate cancer with color Doppler ultrasound for almost 2 decades.

DEFINITION OF FOCAL THERAPY:

Focal therapy is a generic term for destroying the tumors only

by treating a portion of the prostate, and leaving the prostate gland intact. There is no consensus of opinion on the method of focal therapy. Some researchers treated only areas of known cancer while others have tried to treat the entire one half of the prostate that showed tumor involvement. There was also an attempt to treat the entire gland excluding the neurovascular bundles. Therefore, some advocate the term "subtotal therapy" instead of "focal therapy". But "focal therapy" is the most common term, now spanning over a decade of research.

The advantages of focal therapy include:

1. It is a minimally invasive procedure using highly accurate imaging to target and destroy only the cancerous tissue within the prostate.
2. The side effects (mainly urinary and sexual dysfunctions) are far less frequent and severe than other conventional therapies.
3. If it fails, other currently available treatment options remain viable. In other words, it will not burn the bridge behind you.
4. It usually performed as an out-patient basis, if not an overnight hospital stay.
5. Recuperation from the procedure is mostly uneventful and quick.

The disadvantages of focal therapy include:

1. It is not widely available. The patient may need to travel to find an expert.
2. Parts of the procedure may not be covered by insurance for some men. The patient should ask about cost, insurance, etc.

TARGETED FOCAL (SUBTOTAL) CRYOABLATION

Focal (subtotal) cryotherapy is defined as the less than complete ablation of the prostate gland with freezing or ice.

A known tumor site (lobe) is aggressively treated, but the contralateral (opposite side) lobe of prostate tissue and surrounding structures are spared. This method offers targeted local cancer control, while preserving urinary continence and sexual potency for most. (See Table 1)

In the PSA era, many cancers are detected at an early organ contained stage, and may be confined in one lobe of the prostate. As many as 35% of clinically localized prostate cancers are unifocal and may be candidates for focal therapy. A tumor less than 0.5cc is used as a criterion for low-volume disease; this may not require any type of intervention. Others argue that even tumors smaller than 0.5 cc may be clinically aggressive and may require intervention. It is indeed a burden to identify the proper candidates for focal therapy.

PATIENT SELECTION FOR FOCAL CRYOABLATION:

Optimal patient selection criteria are not clearly defined nor agreed upon within the urology field. However, it is essential that the patient have unifocal (1 focus lesion) or unilateral (1 side of gland) prostate cancer. We perform a color Doppler transrectal ultrasound and staging biopsy (in addition to the initial extended blind biopsy that usually was already performed by the patient's physician). Some centers advocate more invasive saturation biopsy to confirm the known tumor site but more importantly to reconfirm the absence of any additional tumor in the other lobe. If an unexpected clinically significant cancer is found in the other lobe by repeated biopsy, the patient is excluded as a candidate for focal therapy. In general, low-risk prostate cancers are preferred but moderate to high-risk cancers in men with medical co-morbidities can also be considered. Only unilaterality, not pre-operative PSA level or tumor differentiation (Gleason grade), are the defining issue. Men

with extracapsular extension or seminal vesicle invasion can also have focal therapy.

Focal cryotherapy can also be offered as a salvage therapy (failure after any type of organ preserving treatment, such as radiation, cryotherapy, HIFU, and photodynamic therapy) as long as the recurrent disease is unilateral in location.

METHODS:

The cryoablation procedure uses extremely cold temperature (ice) to ablate the tissue. The third generation technology uses argon gas for cooling and helium for warming. It consists of two freeze and thaw cycles after the placement of a urethral warming device. Under general anesthesia or spinal block, cryoprobes are placed percutaneously under ultrasound guidance at strategic locations to be frozen. If seminal vesicle invasion is present, it would also be frozen by placing one of the probes in the lumen of the seminal vesicle. Usually 2-4 cryoprobes are used, depending on the size of the lesion and the size of the prostate. (See Figure 1) A single probe may be placed in the contralateral lobe close to the urethra and external sphincter in case heating is necessary to protect these organs (simultaneous heating and cooling). This can be a useful technique if the prostate gland volume is small. This combination of aggressive freezing at targeted locations within the prostate while maintaining the integrity of the urethra, external sphincter, and contralateral lobe, including the neurovascular bundle, is the premise of focal cryoablation.

Cryotherapy is an outpatient based procedure performed as same day surgery. However, if the patient visits from long distance he will have overnight observation in the hospital and discharged following day with a Foley catheter in place. The

catheter is usually removed in 3-5 days. (See Figure 1)
As a follow up PSA levels should be checked once every three months for one year and every six months thereafter. Biopsy is encouraged at one year, two years, five years, and anytime there is a PSA elevating trend.

RESULTS:

Based on multiple publications in the literature (See Table 1.), the overall oncologic outcome of focal cryoablation therapy is encouraging. We recently published focal cryotherapy data for clinically unilateral, low-intermediate risk prostate cancer in 73 men with a median follow up of 3.7 years (1-8.5 years). Complete follow up was available in 70 patients. No patient died or developed metastasis. Pre-cryotherapy PSA was 5.9 ng/ml and Gleason score was 6 (n=30) and 7 (n=43). More patients had Gleason 7 (Intermediate risk) than Gleason 6 (Low risk) cancers. Post-cryotherapy mean PSA was 1.6 ng/ml (70% reduction). Of 48 patients undergoing post-cryotherapy biopsy, 36 (75%) had negative biopsies and 12 had positive biopsy for cancer. Reviewing the 12 cases with positive biopsies, 11 cancers were seen in untreated lobe and one in the treated lobe. Complete urinary continence and potency sufficient for intercourse were documented in 100% and 86% of patients, respectively. Matched-pair comparison of focal cryotherapy and robot assisted laparoscopic prostatectomy revealed similar oncologic outcome, defined as needing salvage treatment.

DISCUSSION:

Appropriate patient selection and standardized follow-up protocols remain controversial issues in focal therapy for prostate cancer. In our opinion, image visibility of prostate cancer is extremely important for proper patient selection, precise cancer mapping that allows accurate therapeutic targeting. We believe the encouraging oncologic outcomes (cancer responses) of our study were a result of

accurate TRUS-based sextant and color Doppler targeted biopsy and mapping.

Follow-up biopsies in the treated side confirmed no evidence of cancer in 98% (47 of 48). Ohori et al reported that the index (primary) lesion typically accounts for 80% of the tumor bulk, with the remaining 20% comprising smaller secondary lesions. Removing or destroying the index tumor might eliminate the possibility of distant metastasis in the future and overall tumor burden by 90%.

Similarly, Villers et al. reported that 80% incidental cancers were <0.5 ml. In our series, the follow-up systemic biopsies from the untreated, contralateral, previously negative lobe revealed newly diagnosed cancers in 11 patients: most were small volume Gleason 6, but two were Gleason 7 = 3+4 and one was Gleason 7 = 4+3. However, 8 of 11 patients elected to undergo active surveillance for these newly diagnosed relatively low risk cancers. Consequently, only 4 (5.7%) of 70 patients underwent salvage treatment. Three patients chose focal cryotherapy and one had radiation therapy. In matched-pair radical prostatectomy series, 6 patients (8.8%) underwent salvage therapy.

Given the potential for cancer multifocality (more than 1 tumor) and/or bilaterality (both sides of prostate), as well as potential under-diagnosis at the entry biopsy, follow-up biopsies for the untreated lobe are mandatory.

Following focal cryoablation, current PSA criteria have a limited role in predicting local recurrence in the treated lobe or progression in the untreated lobe. It is noteworthy that in our series, even patients with biopsy-proven recurrence had well controlled PSA levels (range: 0 – 1.5ng/ml). In other words, our mandatory post-cryotherapy biopsies revealed cancer before a significant PSA rise. Interestingly, percent decrease of PSA from pre to post-cryotherapy was

70%. Since untreated tissue remained in the contralateral lobe, this 70% PSA decrease after hemi-ablation seems a

reasonable benchmark to indicate successful ablation of the index lesion, based on prior data that the index cancer accounts for 80% of entire cancer volume in a given patients. A major limitation of our study includes the fact that 22 patients (33%) refused follow-up biopsy, mainly due to their negligible post-treatment PSA level (<1 ng/ml).

TABLE 1 - FOCAL CRYO PUBLICATIONS

Author	Orlik	Bahn	Lambert	EBis	*Ward
n=No of Patients	(n=48)	(n=73)	(n=25)	(n=60)	(n=1160)
Average age	n/a	64	68	69	68
Average Follow up Years	4.5	3.7	2.3	1.3	1.8
Gleason: No. of patients (%)	n/a	6: 30 (41) 7: 43 (59)	6: 13 (52) 7: 12 (48)	<7: 47 (78) 7: 12 (20) >7: 1 (2)	<7: 844 (74) 7: 249 (21) >7: 64 (6)
Clinical Stage: No. of patients (%)	n/a	T1c: 41 (56) T2a: 31 (43) T2b: 1 (1)	T1c: 25 (100)	T2a: 55 (92) T2b: 5 (8)	T2a: 1013 (87) T2b: 147 (13)
Stable PSA (%)	94	85	85	80.4	75
Incontinence (%)	0	0	0	3.6	1.6
Potency Maintained (%)	90	86	71	71	58

*Data from CCOLO registry

CONCLUSION:

Imaging visibility on scanning is necessary to achieve precise cancer mapping. Focal cryotherapy represents a modification of the whole gland approach and appears to offer acceptable oncologic effectiveness with reduced treatment related adverse events. The risk of incomplete eradication of cancer is likely to be small in appropriately selected men. It is precisely those types of patients who are presently confounded by the choice between active surveillance and a more complex whole-gland treatment. There are other competing technologies that can be applied to focal or subtotal therapy. Some of them are not ready for clinical use, but are intriguing. The most important component in any focal therapy is the precise imaging. Without clear identification of the tumor, its location and stage of the disease, focal therapy can be a blind approach with potential for suboptimal outcome.

Other Competing Focal Ablation Technologies

HIGH INTENSITY FOCUSED ULTRASOUND (HIFU)

In HIFU, ultrasound beam is focused at a small fixed point to create high power that produces heat ranging from 80 to 100 degrees C. It is proven to be lethal temperatures that will create tissue ablation. It has been applied towards organ-confined, localized prostate cancer treatment as a primary treatment or as salvage therapy (after failed any organ preserving therapy, such as radiation, cryoablation, etc). Recently the help of MRI scan is applied to enhance the targeting the cancer in addition to the ultrasound imaging. It is a quite popular procedure in Europe and Asia. This technology just received the FDA clearance, although patients should still ask about insurance coverage and costs.

HIFU is performed as an outpatient procedure, usually under spinal anesthesia. Real-time ultrasound imaging guidance and/or magnetic resonance guidance is used to position the probe and to monitor the procedure. Pulses of HIFU are directed at the targeted section of the prostate, inducing tumor necrosis.

A few published outcome data show fairly good cancer control and acceptable rates of complications. The study populations in the studies are all small and all had short follow up. One study reported the treatment failure (defined as any positive biopsy and/or need for salvage therapy prompted by rising PSA levels) was observed in 42%. Other studies reported the rates of positive biopsy at 12 months were in the range of 8-23%. The sexual and urinary dysfunction rates are fairly low (< 10%).

*“Although
HIFU recently
received FDA
clearance,
patients should
still ask about
insurance
coverage
and costs.”*

FOCAL BRACHYTHERAPY: LOW-DOSE RATE (LDR) AND HIGH-DOSE RATE (HDR)

LDR brachytherapy is typically used to treat the entire prostate by implanting permanent radioactive seeds that allow the delivery of high dose radiation to the prostate while limiting the collateral damages. The use of whole-gland brachytherapy for localized prostate cancer has been well established. Focal LDR brachytherapy is to target the cancerous area only in the prostate while sparing the rest of the prostate tissue. It will further reduce the radiation toxicity related complication. It usually performed under transrectal ultrasound guide.

HDR brachytherapy (temporary placement of radioactive material in the prostate) can be also used as a focal therapy modality. There is only limited information in the literature related to the clinical outcome of focal brachytherapy, either as LDR or HDR.

PHOTODYNAMIC THERAPY (PDT) OR VASCULAR-TARGETED PHOTODYNAMIC THERAPY (VPD)

This technique describes the destruction of a target tissue via the administration of an inactive, light sensitive agent (photosensitizer) and the local application of light in the presence of oxygen. The photosensitizer absorbs a laser light and transfers this energy to the tissues, creating cell destruction. One recently developed photosensitizer has a tendency of staying within the tumor vascular network. Due to this reason, when PDT is applied, extensive vascular damage is created that leads to tissue necrosis. It is referred to "Vascular-Targeted PDT." One small study of 13 patients who had salvage VPD reported 8/13 biopsies negative at 6 months. Two patients experienced urethro-rectal fistulae. This therapy is not approved for prostate cancer in the US, but there are a few clinical trial sites.

NANOKNIFE

NanoKnife technology is known as an Irreversible Electroporation. Instead of using extreme heat or cold, the NanoKnife system uses electrical currents to treat the tumors. The device known as the NanoKnife passes an electrical current through the tumor. The expected electric injury is a creation of permanent nano-meter sized very small holes (pores) in the tumor cells, leading to the death of the cells. Ultrasound or other imaging techniques such as CT or MRI is used to focus the electric current precisely on the tumor. One study in the literature reported about 75% disease free survival at 10 years.

SUGGESTED READING

1. Bahn DK, et al: Focal prostate cryoablation: Initial results show cancer control and potency preservation. J of Endourology. Vol 20, No 9, p688-692, Sept. 2006
2. Onik G, et al: "Male lumpectomy":focal therapy for prostate cancer using cryoablation. Urology. 2007 Dec;70 (suppl):16-21
3. Jones JS. Et al: Focal or subtotal therapy for early stage prostate cancer. Current treatment options in oncology.

Springer, Boston. Vol 8, No 3, June 2007

4. Gillett MD et al: Tissue ablation technologies for localized prostate cancer. Mayo Clin Proc Dec 2004;79(12):1546-1555

5. Polascik TJ et al: Focal therapy for prostate cancer. Current opinion in urology 2008, 18:269-274

6. Lambert EH et al: Focal cryosurgery: Encouraging health outcomes for unifocal prostate cancer. Urology. 69(6), 1117-1120

7. Bahn DK et al: Focal cryoablation of prostate: A review. The ScientificWorld Journal (2008) 8, 486-491

8. Nguyen H, Bryan BS et al: Focal cryotherapy in the treatment of localized prostate cancer. Cancer Control 2013, Vol 20, No 3

9. Bahn DK, de Castro Abreu A, et. al: Focal cryotherapy for clinically unilateral, low-intermediate risk prostate cancer in 73 men with a median follow-up of 3.7 years. European Journal of Urology 2012:62 (1):55-63

10. Babaian RJ, Donnelly B, Bahn DK, et al.: Best practice statement on cryosurgery for the treatment of localized prostate cancer. J Urol. 2008;180(5):1993-2004

11. De Castro Abreu A, Bahn DK, et al: Salvage focal and salvage total cryoablation for locally recurrent prostate cancer after primary radiation therapy. BJUI 2013:112, 298-307

12. Tong W, G Cohen, et al: Focal low-dose rate brachytherapy for the treatment of prostate cancer. Dovepress, April 2013